



UDC 639.2.09: 616.995.132

INFECTION OF PREDATORY FISH WITH LARVAE OF *EUSTRONGYLIDES EXCISUS* (NEMATODA, DIOCTOPHYMATIDAE) IN THE DELTA OF THE DNIPRO RIVER AND THE DNIPRO-BUH ESTUARY IN SOUTHERN UKRAINE

S. L. Goncharov¹, N. M. Soroka², I. Y. Pashkevich³, A. I. Dubovyi⁴, A. O. Bondar¹

¹Mykolayiv National Agrarian University
Heorhiia Honhadze st., 9, Mykolayiv, 54020 Ukraine
E-mail: sergeyvet85@ukr.net

^{2,3}National University of Life and Environmental Sciences of Ukraine,
Potekhin st., 16, Kyiv, 03041 Ukraine

⁴The University of Auckland, Department of Molecular Medicine and Pathology,
Auckland, 85 Park Road, 1023 New Zealand.

Infection of Predatory Fish with Larvae of *Eustrongylides excisus* (Nematoda, Dioctophymatidae) in the Delta of the Dnipro River and the Dnipro-Buh Estuary in Southern Ukraine. Goncharov, S. L., Soroka, N. M., Pashkevich, I. Y., Dubovyi, A. O., Bondar, A. O. — The article describes occurrence and distribution of *Eustrongylides* trematodes in fish in the waters of the Dnipro-Buh estuary and the delta of Dnipro River in Mykolaiv and Kherson Region. Study was conducted in 2015–2016. This parasite was found in natural water reservoirs in Mykolaiv and Kherson region in following fish species: *Sander lucioperca* (Linnaeus, 1758), *Perca fluviatilis* (Linnaeus, 1758) and *Esox lucius* (Linnaeus, 1758). Ichthyopathological investigation of 346 fishes was conducted. Parasites were observed in abdominal cavity, muscle tissue, wall of gastro-intestinal tract, gonads and hepatopancreas. *P. fluviatilis* was the most affected species, prevalence of infection was 85.1 %. Less infected were *S. lucioperca* and *E. lucius*, with the prevalence of infection 58.1 % and 58.9 % respectively. Mean prevalence of infection of predatory fish in studied reservoirs was 70.5 %. The intensity of infection was the highest in perch (1–14 nematodes per fish). The lowest intensity of infection was found in pike-perch (1–9 nematodes per fish).

Key words: occurrence, *Eustrongylides excisus*, predatory fish, intensity of infection, prevalence, Dnipro-Buh estuary, delta of the Dnipro River.

Eustrongylides excisus, Jägerskiöld, 1909 is a nematode that belongs to the family Dioctophymatidae and maybe a potential threat to human health (Ljubojevica, 2015). The species was described by Egersheld in 1909 as a result of the study of nematodes found in the glandular stomach of cormorants (Karmanova, 1968).

Predatory fish such as pike-perch (*Sander lucioperca*), perch (*Perca fluviatilis*) and pike (*Esox lucius*) can spread the pathogen among piscivorous birds (Branciani, 2016). *Eustrongylides* spp. were recognized as zoonotic parasites dangerous for humans. Infection occurs when insufficiently thermally processed fish and fish products are consumed (Wittner, 1989; Narr, 1996).

Nematode *E. excisus* has a complex lifecycle, where a number of piscivore birds, particularly Ciconiiformes, Anseriformes, Gaviiformes and Pelecaniformes, act as definitive hosts (Novakov, 2013). In these birds,

parasite's eggs with developing first-stage larvae are passed through faeces and are ingested by aquatic oligochaetes of Tubificidae and Lumbricidae families, the first intermediate hosts. The second and the third larval stages develop in the coelom or internal organs of these oligochaetes (Karmanova, 1968; Lichtenfels, 1985; Spalding et al., 1993). The second intermediate host could be planktivorous and benthivorous fish which ingests infected oligochaetes (Moravec, 1994). Predatory fish may also take part in the development cycle of *E. excisus*, particularly pike-perch (*Sander lucioperca*), perch (*Percfluviatilis*) and pike (*Esox lucius*) becoming a paratenic host of the parasite, capable of infecting birds (Novakov, 2013; Metin, 2014; Moshu, 2014).

It was observed by a number of scientists that nematodes *E. excisus* may use some amphibians and reptiles as paratenic hosts, particularly marsh frog (*Pelophylax ridibundus* Pallas, 1771), cane toad (*Rhinella marina* Linnaeus, 1758), dice snake (*Natrix tessellata* Laurenti, 1768) (Karmanova, 1968; Melo, 2015; Gagut, 2015).

E. excisus is widespread in the world. Cases of infection with *E. excisus* were reported in Serbia, Romania, Turkey, Brazil, the USA, Italy, Iran, Azerbeidjan, Czech Republic, Russia and Ukraine (Lichtenfels et al., 1985; Pozzoki, 2007; Novakov, 2013; Soylu, 2013; Yesipova, 2013; Melo, 2015; Fedorov, 2014; Noei, 2015; Branciaro, 2016).

The aim of this study was to investigate the occurrence of *E. excisus* in three the most common species of predatory fish in the Dnipro-Buh estuary and delta of the Dnipro River.

Methods

During the years 2014–2016, 346 specimens of three species of predatory fish were studied: perch — 155, pike-perch — 74, and pike — 117. Fish was randomly sampled during routine surveillance, caught on fishing rods or purchased from fishermen working in the same area. Fish sampling was conducted along the coastline of the Dnipro-Buh estuary and delta of the Dnipro river, within the administrative borders of Mykolayiv Region (near the village of Dniprovske in Ochakiv District — 46°37'48.45" N, 31°51'43.72" E, Cape Adzhigol — 46°37'01.98" N, 31°47'13.41" E) and in Kherson region (near the villages Aleksandrovka — 46°35'59.56" N, 32°07'12.75" E, Stanislav — 46°34'24.00" N, 32°10'33.59" E, Sofivka — 46°35'17.09" N, 32°15'57.41" E, of Belozersky district; nearby villages Rybalche — 46°28'40.63" N, 32°12'15.99" E and Heroyske — 46°30'27.88" N, 31°54'54.83" E, of Hola Prystan district) (fig. 1).

Ichthyopathological investigation was conducted in all predatory fish — perch, pike-perch and pike. Clinical examination began with careful examination of the body surface. Oral cavity and gills were examined separately. Longitudinal dissection was performed on a ventral side of the body from anus to head. Each organ was extracted separately, including intestine with its content. Muscles were dissected in multiple areas and each section was carefully investigated. Brain, spinal cord and eye lens were also examined (Bikhovskaya-Pavlovskaya, 1985).

During the autopsy, red nematode larvae, approximately 30–55 mm long were found. Parasites were fixed in 70 % ethanol. After fixation, nematodes were placed into lactic acid solution for clarification. Larvae were placed in a Petri dish and examined under a microscope Micromed XS-6320. The identification of the species was based on morphometric analysis and according to keys provided by Bauer (1987).

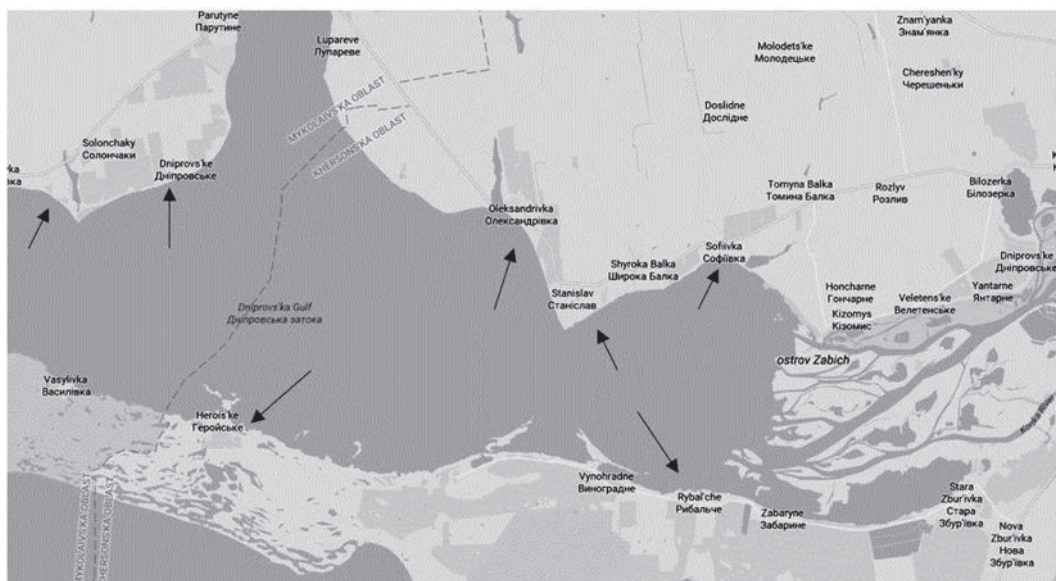


Fig.1. Sites of the material collection.

Results and discussion

During postmortem examination of fish, nematodes were found in intercostal and abdominal muscles. Occasionally parasites were found in the dorsal muscles as well. The larvae were found as dense coils or wide rings directly on the internal side of the abdominal wall in semitranslucent capsules (fig. 2).

Larvae of nematodes were also found in tissues of hepatopancreas and gonads, and on the surface of internal organs (fig. 3).

Some parasites were found in the wall of the stomach, in the capsules formed from the host tissues (fig. 4).

E. excisus can cause an increase in volume of the abdominal cavity, however, the death of fish is relatively rare and usually due to the presence of secondary infection (Overstreet, 2003).

It should be noted that in some cases the capsule was observed around the typical signs of inflammation: hyperemia and oedema of surrounding tissue. Particularly prominent signs of inflammation were observed in mesentery and muscles. There were also capsules

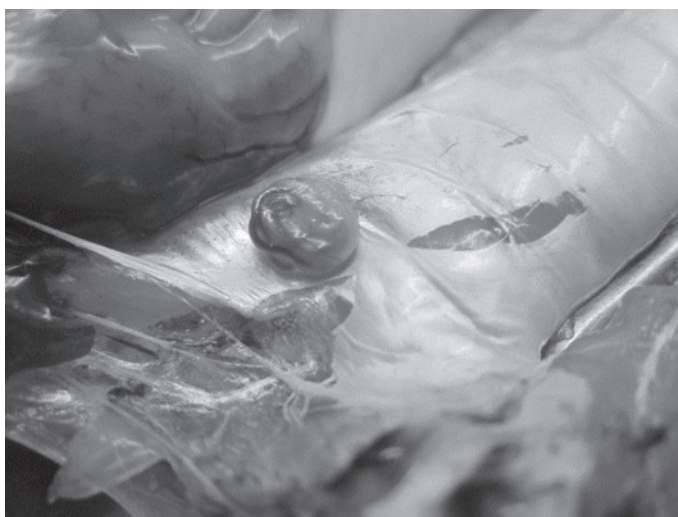

Fig. 2. Larvae of *E. excisus* in, a capsule on the inside of the abdominal wall.

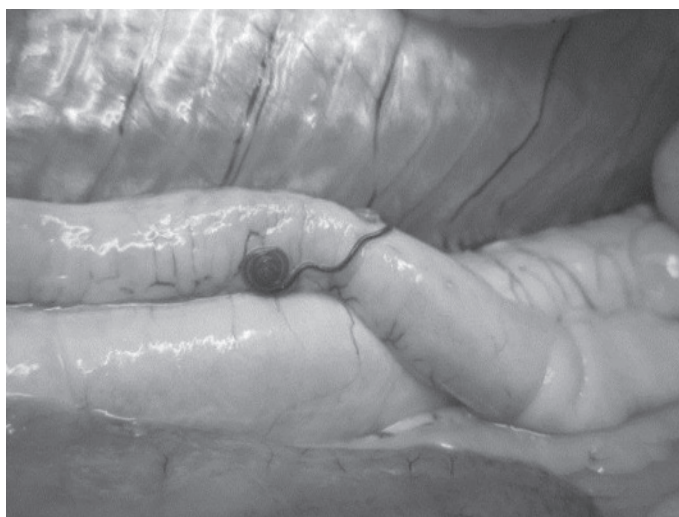


Fig. 3. Larvae of *E. excisus* on the internal organs of pike-perch.



Fig. 4. Caspule with a larva of *E. excisus* in a stomach wall of pike.

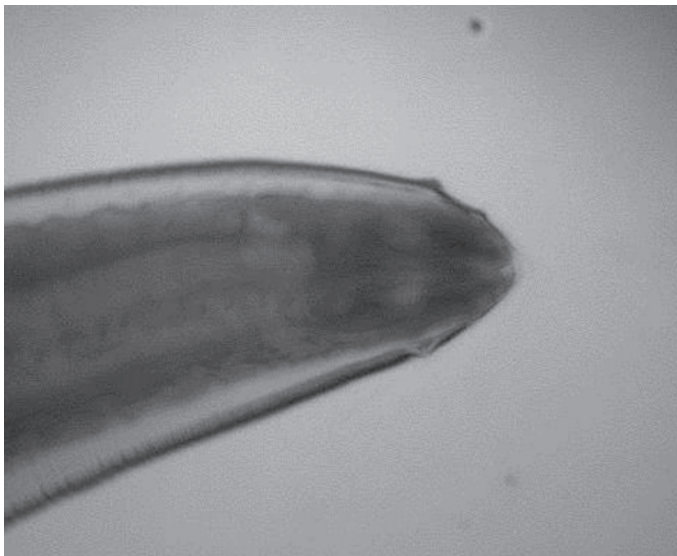

Fig. 5. Anterior end of the body of *E. excisus* larva from pike. Arrows show two circles of papillae. x400 magnification.

with nematodes without any signs of inflammation. Probably, the reactivity of the internal organs and muscles tissues to mechanical injury during parasite migration is different. We believe that such phenomena are also due to time of penetration and migration of larvae in the tissues of the intermediate host.

Extracted larvae were alive and had a length up to 55 mm, width 0.5–1.8 mm. Posterior to the nerve ring, 7 cervical glands were observed. Nerve ring was located 0.092–0.0105 mm from the anterior end of the body. The length of the oesophagus varied from 2.44 to 4.6 mm. The body was dark red, covered with the cuticle, without spikes or papillae. The anterior end was flattened and had two circles of papillae with 6 papillae in each circle (fig. 5).

Papillae of the exterior circle were shorter and nipple-shaped, while papillae of the inner circle were longer and finger-shaped. The posterior portion of the body was thickened and narrowed toward the end. The anus was located terminally.

In some larvae of *E. excisus*, S-shaped bend of intestinal tube was observed posterior to the nerve ring (fig. 6).

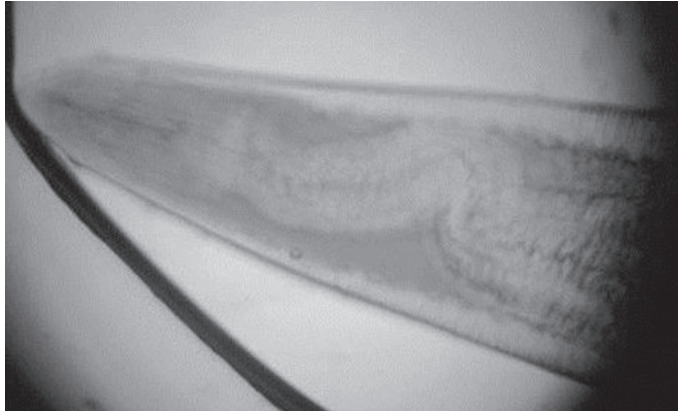


Fig. 6. S-shaped bend of intestinal tube in *E. excisus* larva from perch. x400 magnification.

Karmanova (1968) indicated the presence of sex dimorphism in this nematode, arguing that larvae with narrowed end develop into females and those with the thickened end — into males. Dogel (1939) reported poorly developed sex tube in larvae of *E. excisus*.

The analysis of the species composition of infected fish showed that perch was the most affected by the parasite, with prevalence of infection 85.1 %. In pike-perch and pike prevalence of infection was 58.1 % and 58.9 %, respectively. Intensity of infection was the lowest in pike-perch— 1–9 larvae in one fish (table 1).

Our results suggest, that *E. excisus* is distributed evenly in the waters of the Dniro-Buh estuary and delta of the Dniro River. The mean prevalence of infection in the studied reservoirs was 70.5 %.

In Ukraine, *E. excisus* was registered in different parts of the reservoir in Zaporizhzhya in perch (*P. fluviatilis*), in which prevalence of infection was 65 %, intensity of infection — up to 68 parasites in one fish. Larvae of *E. excisus* were also found in catfish (*Siluris glanis*) (prevalence of infection 12 %) and pike-perch (*S. lucioperca*) (prevalence of infection 25 %). In another study, reported much higher prevalence in perch population in Zaporizhzhya reservoir, 72 % on average with up to 100 % prevalence in some areas. This nematode was also registered in fishes of the family Gobiidae in the Azov and Black Sea (Korniychuk, 2008).

E. excisus was reported in a number of countries. Noei (2015) reported the species in *Acipenser persicus* and *Acipenser stellatus* near Iranian coast of the Caspian Sea. Prevalence of infection was 7.66 % and 5 %, respectively. In Lake Trasimeno, Italy, prevalence of infection in perch was 6.84 % (Branciari, 2016). In contrast, in Turkey the prevalence of fish infection with *E. excisus* was higher. Soylu (2013) studied prevalence of parasitic diseases in fish of Sigirci Lake and found, that in perch the prevalence of infection with *E. excisus* was 94.5 % and intensity of infection was 1 to 305 larvae per fish. Similarly, in more recent study Metin (2014) found that prevalence of infection in pike-perch (*S. lucioperca*) reached up to 100 % in Egirdir Lake.

In Serbia, larvae of *E. excisus* in pike-perch (*S. lucioperca*) were first reported in 2013 in fish from the Danube-Tisa-Danube Canal in the city area of Novi Sad (Bjelic-Čabriolo, 2013). The prevalence of infection in *S. glanis* was 11.54 % and intensity of infection reached 256 larvae in one fish (Novakov, 2013). In Romania, prevalence of *E. excisus* infection in pike-perch was 55.58 % (Oprescu, 2015).

Occurrence of *E. excisus* in fish is an important epidemiological issue in many countries, including countries of Europe, Brazil, USA, Middle East, Russia and Ukraine (Lichtenfels, 1985; Pozooki, 2007; Novakov, 2013; Soylu, 2013; Yesipova, 2013; Melo, 2015; Fedorov, 2014; Noei, 2015; Branciari, 2016).

Table 1. Parameters of *E. exciuis* infection in predatory fish in Southern Ukraine

Species of fish	Quantity, no. of fish	Prevalence, %	Intensity of infection, range (larvae/infected fish)
Dnipro-Buh estuary (near the village of Dniprovske in Ochakiv District, Mykolayiv Region — 46°37'48.45" N, 31°51'43.72" E)			
<i>Perca fluviatilis</i>	37	86.4	1–8
<i>Sander lucioperca</i>	8	62.5	1–5
<i>Esox lucius</i>	11	45.4	2–12
Dnipro-Buh estuary (Cape Adzhigol, Mykolayiv Region — 46°37'01.98" N, 31°47'13.41" E)			
<i>Sander lucioperca</i>	18	61.1	1–4
<i>Esox lucius</i>	4	100	1–6
Dnipro-Buh estuary (near the village Aleksandrovka, Bilozerskyi District, Kherson Region — 46°35'59.56" N, 32°07'12.75" E)			
<i>Perca fluviatilis</i>	29	93.1	4–13
<i>Sander lucioperca</i>	12	66.6	1–9
<i>Esox lucius</i>	23	56.5	1–10
Dnipro-Buh estuary (near the village Stanislav, Bilozerskyi District, Kherson Region — 46°34'24.00" N, 32°10'33.59" E E)			
<i>Perca fluviatilis</i>	16	100	1–14
<i>Esox lucius</i>	12	75	1–8
Delta of the Dnipro River (near the village Sofiivka, Bilozerskyi District, Kherson Region— 46°35'17.09" N, 32°15'57.41" E)			
<i>Perca fluviatilis</i>	51	84.3	2–11
<i>Sander lucioperca</i>	13	69.2	3–5
<i>Esox lucius</i>	38	60.5	1–13
Delta of the Dnipro River (near the village Rybalche, Hola Prystan District, Kherson Region— 46°28'40.63" N, 32°12'15.99" E)			
<i>Perca fluviatilis</i>	22	63.6	5–7
<i>Sander lucioperca</i>	9	44.4	1–6
<i>Esox lucius</i>	29	51.7	2–8
Dnipro-Buh estuary (near the village Heroyske, Hola Prystan District, Kherson Region— 46°30'27.88" N, 31°54'54.83" E)			
<i>Sander lucioperca</i>	14	42.8	3–6

Overall, *Eustrongylides* infection remains relatively common in Europe and is on a rise in some areas. The fact, that *E. exciuis* can potentially infect humans rise even more concerns for public health. Officially, the first case of human infection with *E. exciuis* was reported by Guerin in 1982. People who consumed fish and fish products that were not adequately cooked were found infected. Clinically infection caused gastritis and intestinal wall perforations (Guerin, 1982; Deardorff, 1991).

In our opinion, several factors might play a role in high prevalence of *E. exciuis* infection among studied species of fish in the studied area. Firstly, delta of the Dnipro River has different water quality with higher concentration of nutrients and organic compounds, which in turn can facilitate growth of oligochaetes population in that region. There are no current literature data to support this hypothesis and further studies are required. Secondly, remoteness from the cities makes this area very favourable for nesting and habitation of piscivorous birds — definitive hosts of *E. exciuis* (Cole, 2013).

Conclusion

We studied *Eustrongylides* infection of predatory fish in the Dnipro-Buh estuary and the delta of the Dnipro River in Mykolaiv and Kherson Regions. The highest prevalence of infection was found in perch. The mean prevalence of infection in the studied region was 70.5 %, which is comparable to other reservoirs in Ukraine.

Environmental factors that favour the growth of oligochaetes populations may play a role in high prevalence of *E. excisus* infection among fish. Further studies are necessary to establish a causative inference between water quality and size of oligochaete population, as well as effectiveness of water quality improvement on the prevalence of *E. excisus* infection in fish.

References

- Bauer, O., ed. 1987. *The keys to the freshwater fish parasites*. Nauka, Moscow, part 3, 583 [In Russian].
- Bikhovskaya-Pavlovskaya, I. E. 1985. *Parasites of fish: Study Guide*. Nauka, Leningrad, 1–121 [In Russian].
- Bjelic-Čabriolo, O., Novakov, N., Ćirkovic, M., Kostic, D., Popovic E., Aleksic, N., Lujic, J. 2013. The first determination of *Eustrongylides excisus* Jägerskiöld, 1909 — larvae (Nematoda: Dioctophymatidae) in the pike-perch *Sander lucioperca* in Vojvodina (Serbia). Parasitological Institute of SAS, Košice. *Helminthologia*, **50**, 4, 291–294.
- Branziari, R., Ranucci, D., Miraglia, D., Valiani, A., Veronesi, F., Urbani, E. 2016. Occurrence of parasites of the genus *Eustrongylides* spp. (Nematoda: Dioctophymatidae) in fish caught in Trasimeno lake, Italy. *Italian Jour. of Food Safety*, **5**, 6130, 206–209.
- Cole, R. 2013. *Eustrongylidosis*. In: *Field Manual of Wildlife Diseases. General Field Procedures and Diseases of Birds*. Milton Friend & J. Christian Franson. Chap. **29**, 223–228.
- Deardorff, T. L., Overstreet, R. M., 1991. Seafood-transmitted zoonoses in the United States: the fishes, the dishes, and the worms. In: Ward, D. R., Hackney, C. R., eds. *Microbiology of Marine Food Products*, New York, 211–265.
- Dogel, V.A., Bykhovskiy, B.E. 1939. *Fish parasites of the Caspian Sea*. Is. 7. Moscow, 154–156 [In Russian].
- Fedorov, N. M., Firsov, N. F., Soloviev, N. A. 2014. Veterinary and sanitary examination in river perch with *Eustrongylidosis*. *Veterinary pathology*. **3–4**, 68–73 [In Russian].
- Gagut, A. N., Gasso, V. Ya., Yarmolenko, S. V., Kuzmin, Yu. I. 2015. Contamination of dice snake (*Natrix tessellata*) by a nematode *Eustrongylides excisus* (Nematoda: Dioctophymatidae) in conditions of the central steppe Dniester region Biodiversity and the role of animals in ecosystems. Lira, Dnepropetrovsk, 213–214 [In Russian].
- Guerin, P. F., Marapendi, S., Grail, S. L. 1982. Intestinal perforation caused by larval *Eustrongylides*. *Morb. Mort. Week. Rep.*, **31**, 383–389.
- Karmanova, E. M. 1968. *Dioctophymidea of Animals and Man and the Diseases Caused by Them*. Nauka Publishing, Moscow. 1–383 [In Russian].
- Korniyuchuk, Y. M., Pronkina, N. V., Belofastova, I. P. 2008. Nematode Fauna of the round goby *Apollonia (Neogobius) melanostomus* in the Black Sea and Sea of Azov. *Ecology of the sea*, **76**, 17–22 [In Russian].
- Lichtenfels, J. R., Stroup, C. F. 1985. *Eustrongylide* ssp. (Nematoda: Dioctophymatoidea): First Report of an Invertebrate Host (Oligochaeta: Tubificidae) in North America. *Proc. Helminthol. Soc. Wash*, **52** (2), 320–323.
- Ljubojevic, D., Novakov, N., Djordjevic, V., Radosavljevic, V. Pelica, M. 2015. Potential parasitic hazards for humans in fish meat. *Procedia Food Science*, **5**, 172–175.
- Melo, F. T., Melo, C. S., Nascimento, L. C. 2015. Morphological characterization of *Eustrongylide* ssp. Larvae (Nematoda, Dioctophymatoidea) parasite of *Rhinella marina* (Amphibia: Bufonidae) from Eastern Amazonia. *Braz. J. Vet. Parasitol.*, Jaboticabal, 7–12.
- Metin, S., Didinen, B. I., Boyci, Y. O. 2014. Occurrence of *Eustrongylides excisus*, Jägerskiöld, 1909 — larvae (Nematoda: Dioctophymatidae) in Pikeperch (*Sander lucioperca*) in Lake Egirdir. *Egirdir Su Ürünleri Facütesi. Dergisi*, **10** (1), 20–24.
- Moravec, F. 1994. *Parasitic nematodes of freshwater fishes of Europe*. Kluwer Academic Publishers, VI, 1–470.
- Moshu, A. 2014. *Helminths of fish ponds between the rivers Dniester and Prut, potentially dangerous to human health*. Eco-Tiras, Kishineu, 1–88 [In Russian].
- Narr, L. L., O'Donnell, J. G., Libster, B., Alessi, P., Abraham, D., 1996. *Eustrongylidiasis* — a parasitic infection acquired by eating live minnows. *J. Am Ost Assoc.* **96**, 400–2.
- Noei, M. R., Ibrahimov, S., Sattari, M. 2015. Parasitic worms of the Persian sturgeon, *Acipenser persicus* Borodin, 1897 from the southwestern shores of the Caspian Sea. *Iranian Jour. of Ichthyology*, **2** (4), 287–295.
- Novakov, N., Bjelic-Cabrilo, O., Ćirkovic, M., Ljubojevic, D., Lujic, J. 2013. *Eustrongylidosis* of European Catfish (*Silurus glanis*). *Bulg. J. Agric. Sci.*, Supplement 1, 72–76.

- Overstreet, R. M. 2003. Presidential address: flavor buds and other delights. *Journal of Parasitology*, 89, 1093–1107.
- Pazooki, J., Masoumian, M., Yahyazadeh, M., Abbasi, J. 2007. Metazoan Parasites from Freshwater Fishes of Northwest Iran. *J. Agric. Sci. Technol.*, 9, 25–33.
- Soylu, E. 2013. Metazoan Parasites of Perch *Perca fluviatilis* L. from Lake Sığircı, Ipsala, Turkey. *Pakistan J. Zool.*, 45 (1), 47–52.
- Spalding, M. G. Forrester, D. J., 1993. Pathogenesis of *Eustrongylides ignotus* (Nematoda: Dioctophymatidae) in Ciconiiformes. *Journal of Wildlife Diseases*, 29, 250–260.
- Yesipova, N. B. 2013. The spread of parasitic nematodes in fish *Eustrongylides excisus* Zaporozhye (Dnipro) reservoir. *Modern probl. of theor. and pract. ichthyology: materials VI International Ichthyological Scien. and Pract. Conf. Ternopi.* 86–88 [In Russian].
- Wittner, M., Turner, J. W., Jacquette, G., Ash, L. R., Salgo, M. P., Tanowitz, H. B., 1989. *Eustrongylidiasis* — a parasit infection acquired by eating sushi. *New Engl. J. Med.*, 320, 112.

Received 30 November 2017

Accepted 9 February 2018